

# Mycetoma caused by *Phellinus* species: a rare case from Brazil

Luís Arthur Brasil Gadelha-Farias<sup>1,2,\*</sup>, Lucas Mustafa-Aguiar<sup>3,4</sup>, Gabriela Studart-Galdino<sup>3,5</sup>, Silvine Praciano-Bandeira<sup>1,6</sup>,  
Giovany Gomes-Capistrano<sup>3,7</sup>, Paulo Roberto Arruda-Tavares<sup>3,8</sup>, Glauca Morgana de Melo Guedes<sup>3,9</sup>, Jaime David Acosta-España<sup>10</sup>

## Abstract

Mycetoma is a chronic and slow-developing granulomatous disease characterized by the triad of large painless tumour-like subcutaneous swellings, the formation of sinuses, and discharge that usually contains grains. *Phellinus* spp. are saprophytic wood-decaying filamentous basidiomycetes. They are an under-recognised cause of invasive fungal infections and are rarely reported worldwide. We report a 59-year-old male patient with mycetoma caused by *Phellinus* spp. The diagnosis was confirmed with clinical examination, magnetic resonance imaging (MRI) study, soft tissue and bone biopsy culture, and polymerase chain reaction. To the best of our knowledge, this is the first reported case of mycetoma due to *Phellinus* spp. without chronic granulomatous disease (CGD).

**Keywords:** Fungal infections; Basidiomycota; *Phellinus*; Mycetoma.

## Micetoma causado por especies de *phellinus*: un caso raro de Brasil

### Resumen

El micetoma es una enfermedad granulomatosa crónica y de lento desarrollo caracterizada por la tríada de grandes inflamaciones subcutáneas similares a tumores indoloros, la formación de los senos nasales y secreción que generalmente contiene granos. *Phellinus* spp. son basidiomicetos filamentosos saprofitos que descomponen la madera. Son un poco reconocido causa de infecciones fúngicas invasivas y rara vez se informan en todo el mundo. Presentamos un paciente masculino de 59 años con micetoma causado por *Phellinus* spp. El diagnóstico se confirmó con examen clínico, estudio de resonancia magnética (RM), cultivo de biopsia de tejido blando y óseo y reacción en cadena de la polimerasa. A lo mejor que sepamos, este es el primer caso reportado de micetoma debido a *Phellinus* spp. sin enfermedad granulomatosa crónica (EGC).

**Palabras clave:** Infecciones por hongos; Basidiomycota; *Phellinus*; Micetoma.

### Introduction

Mycetoma is a chronic and slow developing granulomatous disease characterized by large painless tumour-like subcutaneous swellings, formation of sinuses, and discharge that usually contains grains. Although it may occur in various countries, it is endemic in Sudan, Mexico, and India, and frequent in Brazil and Argentina<sup>1</sup>. It can be caused by either fungi or bacteria. The feet and legs are the most commonly affected regions, but any body part can be affected<sup>1,2</sup>. We report the case of a 59-year-old male patient with mycetoma caused by *Phellinus* spp., a basidiomycete genus. The diagnosis was confirmed with clinical examination, magnetic resonance imaging (MRI), soft tissue and bone

biopsy, culture, and polymerase chain reaction. There have been case reports of chronic granulomatous disease (CGD) complicated with subcutaneous abscess due to *Phellinus* spp.<sup>3,4</sup> Fungal infections related to *Phellinus* spp. are an emerging disease in CGD patients, but this remains a rare condition in patients without CGD<sup>5</sup>. To the best of our knowledge, this is the first reported case of mycetoma due to *Phellinus* spp. without CGD.

### Case report

Our patient presented with a 3-year history of foot swelling and progressive increase in size. He also complained about episodes of pain and the emergence of yellow discharges

1 Faculty of medicine, Universidade Federal do Ceará (UFC), Fortaleza, Ceará, Brazil.

2 <https://orcid.org/0000-0002-8978-9903>

3 Internal medicine department, Hospital Universitário Walter Cantídeo (HUWC), Fortaleza, Ceará, Brazil.

4 <https://orcid.org/0000-0003-3842-7459>

5 <https://orcid.org/0000-0003-2760-3162>

6 <https://orcid.org/0000-0002-4051-5645>

7 <https://orcid.org/0000-0002-9078-6208>

8 <https://orcid.org/0000-0003-2989-8144>

9 <https://orcid.org/0000-0002-5469-8120>

10 Hospital Gineco Obstétrico Nueva Aurora, Quito, Ecuador. Universidad de las Américas, Quito-Ecuador. <https://orcid.org/0000-0001-5299-2732>

\* Autor para correspondencia.

Correo electrónico: [luisarthurbrasilk@hotmail.com](mailto:luisarthurbrasilk@hotmail.com)

Hospital São José de Doenças Infecciosas (HSJ), Nestor Barbosa St., Number 315, Fortaleza, 60455-610, Brazil

Recibido: 14/09/2020; Aceptado: 04/12/2020

Cómo citar este artículo: L.A.B. Gadelha-Farias, et al. Mycetoma caused by *phellinus* species: a rare case from Brazil. *Infectio* 2021; 25(3): 197-199  
<http://dx.doi.org/10.22354/in.v25i3.948>

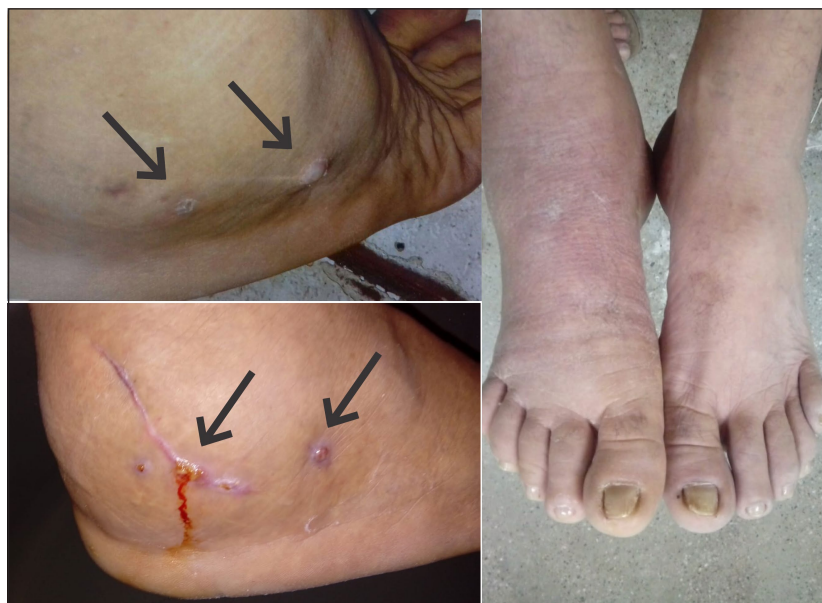

Figure 1.

containing grains. He had previous history of pre-diabetes. Subsequently, the patient reported a wound caused by a piece of wood in childhood. Physical examination revealed a diffuse firm swelling mainly on the lateral aspect of the right foot, and three discharging sinuses (Figure 1). Admission tests revealed discrete anaemia (haemoglobin 12.6 g/dL). Erythrocyte sedimentation rate (70 mm) and C-reactive protein (5.4 mg/L) levels exceeded the normal range.

MRI of the right foot showed overgrowth of soft tissues, bone oedema, and small rounded hyperintensity surrounded by a low-signal-intensity rim with a hypointense dot in the centre, called a dot-in-circle sign (Figure 2). Diagnosis of mycetoma was made and a soft tissue and bone biopsy cultures were performed to identify the etiologic agent. The culture revealed a mycelial colony with bright white and yellow with

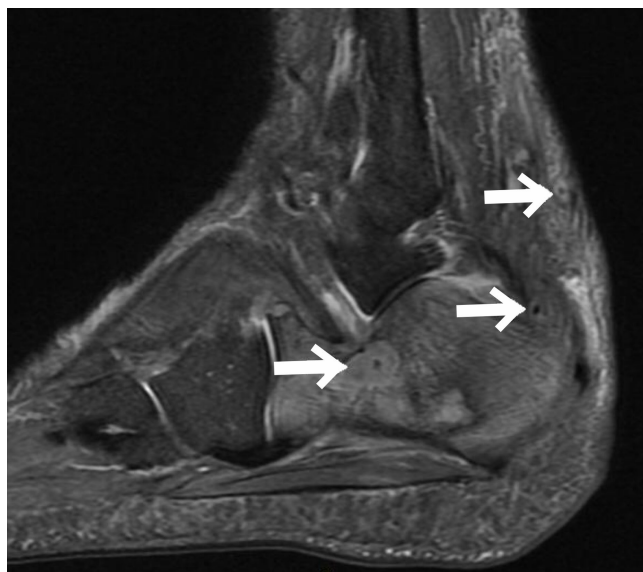

Figure 2.

abundant aerial mycelium on potato dextrose agar (Figure 3). Polymerase chain reaction was performed by sequencing the ITS region, using the panfungal primers ITS1 and ITS4. After obtaining the sequences, the NCBI Blast tool was used and indicated *Phellinus* spp. Therapy was started with voriconazole (6 mg/kg every 12 hours for 2 days followed by a maintenance regimen of 4 mg/kg every 12 hours for 7 days) and amphotericin B lipid-complex (5 mg/kg/day for 4 weeks followed by a maintenance regimen of 5 mg/kg/week for 6 months). After 30 days, he exhibited clinical improvement and the piece wood spontaneous came out (Figure 4). Six months later, the patient remains asymptomatic.

## Discussion

To our knowledge, there is no prior data about *Phellinus* spp. infection with isolated mycetoma in the medical literature. Information regarding treatment is also scarce, but it is believed that lipid formulations of amphotericin B and azoles (such as voriconazole) may be helpful, especially in severe disease. According to current literature, amphotericin B-based regimens may be a better alternative, but voriconazole has also been successfully used to treat *Phellinus* spp. infections<sup>5</sup>. Additionally, identification of pathogen species is difficult because many isolates fail to sporulate and remain sterile in routine mycology media<sup>5</sup>.

In Brazil, mycetoma cases range between 101 and 500 per year<sup>1</sup>. MRI is useful for clinical diagnosis of fungal infection, since it allows evaluation of the invasion and extent of the lesion in most cases. The dot-in-circle sign is indicative of the presence of fungal grains, but not suggestive of the species. Small lesions present better prognosis. Long-term treatments are common, and sometimes ineffective<sup>1</sup>. Although surgical treatment may be necessary in many cases, it was not necessary in our patient.

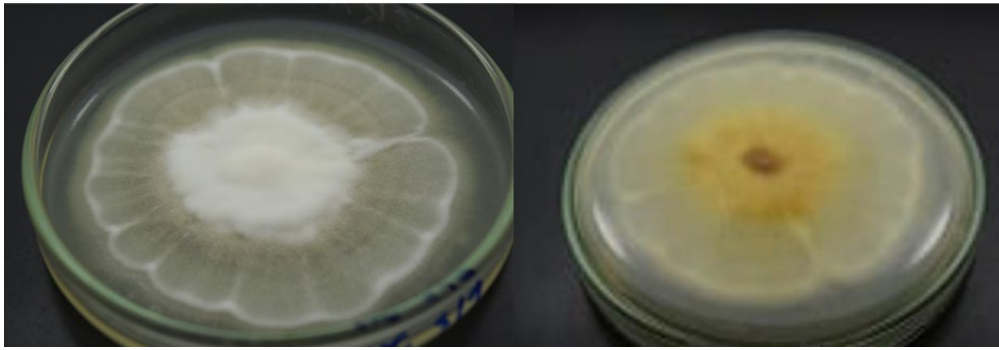


Figure 3.



Figure 4.

We present a rare etiological agent for mycetoma. CGD should be investigated in any patient with identified *Phellinus* spp. infection, although X-linked mutations cannot be evaluated in many health centres. More studies are needed to better understand the management and prognosis of infections caused by *Phellinus* spp.

#### Ethical disclosure

Conflict of interest. None

Sources of funding for our research. Authors

Protection of human and animal subjects. Consent Written informed consent was obtained from the patient for publication of this case report and accompanying images.

Confidentiality of data. No data that identifies patient are revealed

#### References

1. Zijlstra EE, van de Sande WWJ, Welsh O, et al. Mycetoma: a unique neglected tropical disease. *Lancet Infect Dis* 2016; 16(1): 100–112.
2. Van de Sande W, Fahal A, Ahmed SA, et al. Closing the mycetoma knowledge gap. *Med Mycol* 2018; 56(suppl\_1): S153–S164.
3. Shigemura T, Nakazawa Y, Amano Y, et al. Subcutaneous abscess due to the basidiomycete *Phellinus mori* in a patient with chronic granulomatous disease. *Infection* 2015; 43(3): 371–375.
4. Ramesh M, Resnick E, Hui Y, et al. *Phellinus tropicalis* abscesses in a Patient with Chronic Granulomatous Disease. *J Clin Immunol* 2013; 34(2): 130–133.
5. Haidar G, Zerbe CS, Cheng M, et al. *Phellinus* species: An emerging cause of refractory fungal infections in patients with X-linked chronic granulomatous disease. *Mycoses* 2016; 60(3): 155–160.