

Disseminated coccidiomycosis presenting as acute respiratory distress syndrome in a liver posttransplant recipient

Darwin Lambraño-Castillo^{1,2,*}, Alvaro López-Iñiguez^{1,3}, Juan Sierra-Madero¹

Abstract

Acute respiratory distress syndrome (ARDS) is a respiratory process of acute onset, showing on X rays as bilateral pulmonary infiltrates and severe respiratory failure. Coccidiomycosis is an unusual cause of acute respiratory distress syndrome, the incidence of coccidiomycosis in a solid organ transplant recipient ranges from 1.4% to 6.9%, inadequacy of cellular immunity is a well established risk factor for development of coccidiomycosis, less than 1% of patients develop disseminated infection and carrying high mortality, the case that we are presenting adds to the small list of reports documenting the occasionally acute and aggressive nature of the disseminated clinical form of coccidiomycosis.

Key words: Acute respiratory distress syndrome, Coccidiomycosis, solid organ transplant.

Síndrome de dificultad respiratoria aguda (SDRA) como presentación de Coccidiomycosis diseminada, en un paciente receptor de trasplante hepático ortotópico

El síndrome de dificultad respiratoria aguda (SDRA) es un proceso respiratorio de inicio agudo, que se manifiesta en las radiografías como infiltrados pulmonares bilaterales, clínicamente como insuficiencia respiratoria grave, la coccidiomycosis es una causa inusual de síndrome de dificultad respiratoria aguda, la incidencia de coccidiomycosis en receptores de trasplante de órgano sólido varía desde 1.4% a 6.9%, una inadecuada inmunidad celular es un factor de riesgo bien establecido para el desarrollo de coccidiomycosis, menos del 1% de los pacientes desarrollan enfermedad diseminada y alta mortalidad, el caso que presentamos se suma a la pequeña lista de informes que documentan la naturaleza ocasionalmente aguda y agresiva de la forma clínica diseminada de coccidiomycosis.

Palabras clave: síndrome de dificultad respiratoria aguda, coccidiomycosis, trasplante de órgano sólido.

Introduction

Primary pulmonary coccidiomycosis is usually a self-limited illness, the presenting as acute respiratory failure is distinctly uncommon, and has been most frequently associated with underlying immunosuppressive conditions, particularly steroid therapy and massive exposure to *C. immitis*. The highest risk of coccidiomycosis after solid organ transplant occurs in the first year posttransplant, accounting for as many as 70% of cases in one series, in areas of high endemicity, the risk of symptomatic posttransplant coccidiomycosis is increased with history of prior infection, positive serology before transplant, or antirejection therapy, the dissemination is more common in transplant patients occurring in up to 75% of cases, mortality is reported to be from 30% to 63%.

Case description

A 59-year-old male post-transplant liver recipient presented to the emergency department complaining of abdominal pain, nausea, diarrhea and fever. The initial physical exam revealed his blood pressure was 100/62 mm Hg, heart rate of 125/min, temperature 100 °F, respiratory rate 27/min, and oxygen saturation 88% on room air and 92% on 40% venti-mask, the heart exam revealed tachycardia but regular rhythm, a normal S1 and S2 and no murmurs, gallops or rubs. On auscultation of the lung fields, breath sounds were diminished without the presence of adventitious sounds. The abdomen was benign without organomegaly, extremities were normal with absence of clubbing or edema. The patient appeared in discomfort.

1 Infectious Diseases Department. Instituto Nacional de Ciencias Médicas y Nutrición Salvador Zubiran. Ciudad de México.

2 <https://orcid.org/0000-0002-7991-3085>

3 <https://orcid.org/0000-0001-7128-2242>

* Autor para correspondencia.

Correo electrónico: darland19@hotmail.com

Recibido: 13/09/2020; Aceptado: 14/10/2020

Cómo citar este artículo: D. Lambraño-Castillo, *et al.* Disseminated coccidiomycosis presenting as acute respiratory distress syndrome in a liver posttransplant recipient. *Infectio* 2021; 25(3): 189-192
<http://dx.doi.org/10.22354/in.v25i3.946>

The white blood cell count was 5.5 (reference range 5.0 – 12.0 x 10³), with 95% of neutrophils, the hemoglobin was 11.3 gr (reference range 13 – 15.7 gr/dl in men), the platelets count was 76 (reference range 150–450 K/ul). The serum creatinine was 0.94 mg/dl (reference range 0.6–1.2mg/dl), serum sodium was 127 mmol/L (reference range 135–145 mmol/L), serum potassium was 4.3 mmol/L (reference range 3.5–4.5 mmol/L). Serum albumine was 2.8 (reference range 3.4 to 5.4 g/dL) Total Bilirubin 1.26 (reference range 1 to 1.2 mg/dL) ALT 34 AST 29.50 (reference ranges for both 8–40 U/L). Arterial blood gas analysis reported pH 7.46 (7.35–7.45), paco² 20.9 mmHg (reference range 35–45 mmHg), HCO³ 14.4 mmol/L (reference range 22.2–28 mmol/L). Chest CT imaging revealed consolidation areas, multiple lung nodules and ground-glass areas (Figure 1).

Due to the suspicion of invasive fungal infection a bronchoalveolar lavage was requested, after bronchoscopy the patient condition worsened, needing mechanical ventilation, vasopressor support, transferred to the ICU due to severe respiratory failure, a chest X ray revealed lungs with bilateral diffuse consolidation areas (figure 2). The Arterial blood gas analysis reported pH: 7.06 PO₂: 137 PCO₂: 32 HCO₃⁻: 8.8 LACT: 8.76, PaO₂/FIO₂ ratio < 100. Upon admission to the critical care unit, the patient placed under mechanical ventilation pressure control mode and continue antibiotic therapy for acquired community pneumonia in immunocompromised patient, and amphotericin B was added, however the patient died 24 hours after his admission.

The bronchoalveolar lavage culture was negative for bacteria, but the fungus culture produced suspicious filamentous colonies, the cotton blue stain revealed thin and septate hyphae and arthroconidia. (figure 3). Post mortem macroscopic pieces shows a multiple nodular lesions in the lung and liver (fi-

gure 4), microscopic description has typical histologic features, granulomatous inflammation, large thick walled spherules contain variable sized daughter endospores. (figure 5).

Brief discussion

Acute respiratory distress syndrome (ARDS) is a respiratory process of acute onset, showing on X rays as bilateral pulmonary infiltrates and severe respiratory failure, disorders associated with ARDS include direct lesions of the pulmonary parenchyma and lesions indirectly affecting the lung occurs most often in the setting of pneumonia, sepsis, aspiration of gastric contents or severe trauma and is present in ~10% of all patients in intensive care units worldwide. Despite some improvements, mortality remains high at 30–40% in most studies¹. Coccidioidomycosis is a unusual cause of acute respiratory distress syndrome.

Coccidioidomycosis is caused by the dimorphic fungi *Coccidioides immitis*, is found in nature as a saprophytic filament (mould) that produces propagules (arthroconidia) which spread easily in the air, infection caused by *Coccidioides* species occurs after inhalation of aerosolized arthroconidia, with the organism potentially becoming latent within resident and recruited pulmonary phagocytes and cells of the reticuloendothelial system, is endemic to areas of Southwestern United states, Northern Mexico and parts of Central and South America with particular presence in Argentina and Paraguay, are highly infectious to susceptible humans, presents variability of symptoms, 60–80% mild respiratory symptoms, 15 – 35% develop respiratory symptoms in 1 to 4 weeks, 5% will develop progressive symptoms, 1– 5% disseminated forms, dissemination to any organ or tissue can occur, establishing secondary mycosis foci, the fungus can remain viable and latent at and cause clinical manifestation^{2,3}.

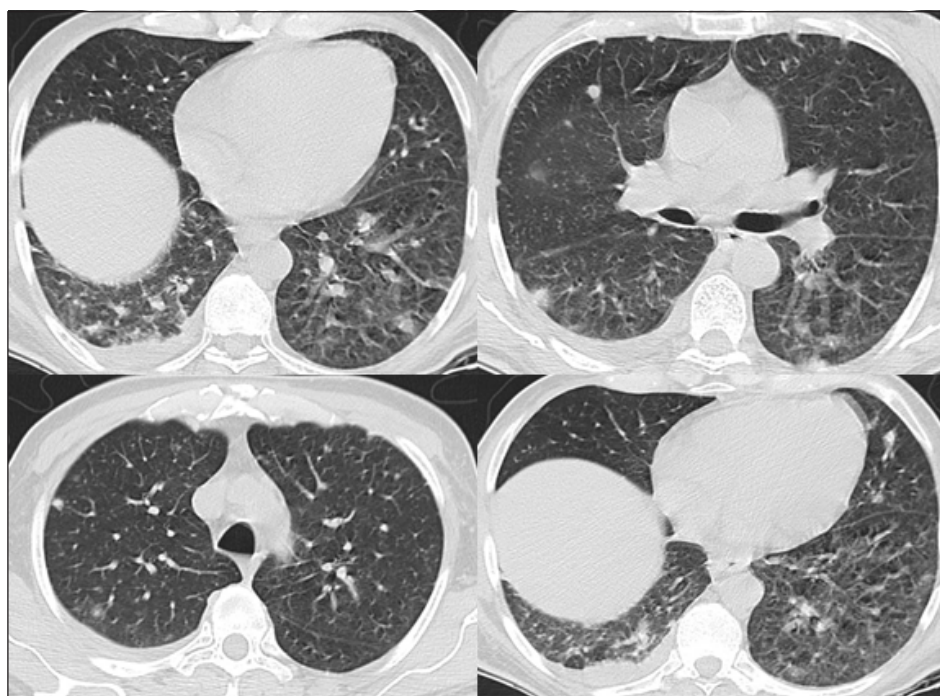


Figure 1. Consolidation areas, multiple lung nodules

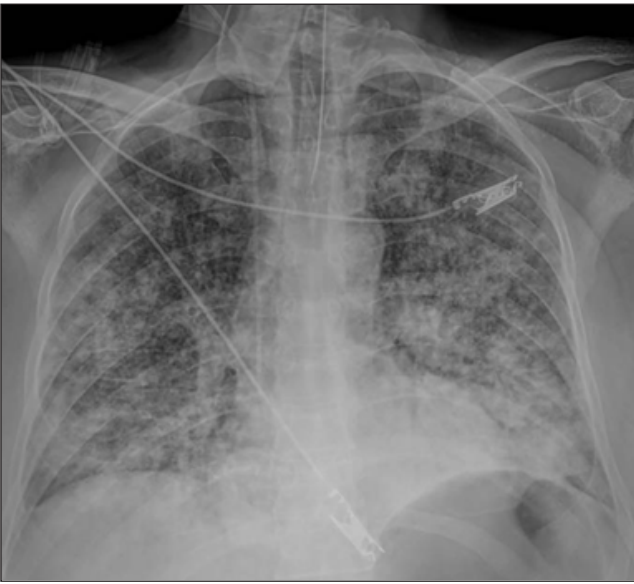

Figure 2. lungs with bilateral difusse consolidation areas.

The present report describes a old man patient post trasplant liver recipient, no residing in the traditional areas of endemicity of *C. Immitis*, a immunocompromised host, with multiple risk factors for a disseminated disease such as age, gender, diabetes mellitus as concurrent immunosuppressing illness, use high-dose corticosteroid treatment and other immunosuppressant drugs tacrolimus and mycophenolate, and your previously labor activities to contact with contaminated dust, especially from uncultivated areas in endemic areas, his relatives comment in the past he works as a civil engineer as a construction operations supervisor in the northern region of Mexico, an endemic area of coccidiomycosis, with the suspicion of exposure of airborne soil particles.

Coccidiomycosis has been reported in solid organ trasplant (SOT) recipients since 1967, the diseases occurs in the first year after trasplant and the incidence of these patients in the endemic areas has been reported as 5 %⁴.

A recent coccidioidal infection or a positive serologic test result at the time of organ transplantation is associated with a rate of dissemination of 75% and a mortality of 30% to 63% without the use of antifungal prophylaxis⁵.

Coccidioidal disease in the immunocompromised host can result from primary infection or from reactivation of old infection. T-cell function deficiencies add the patient at risk for severe or disseminated infection. The receipt of anti-rejection medications or of tumor necrosis factor α inhibitors increases the risk of disseminated coccidioidal disease because of their effect on T-cell function^{6,7}.

In solid organ transplantation is asociated with reactivation of latent infection or primary infection in areas where it is a endemic. In the patient that we are presenting the suspicion is that the reactivation of latent coccidiomycosis, is the most common probable cause form of the disease, which is the most frequent in transplanted patients, since the acquisition through the organ donor was ruled out.

Donor organs may be a source of transmissible agents, particularly viruses, has been a significant concern throughout the era of solid-organ transplantation, Although it is less common, the transmission of fungi^{9,10}. In this case the results of postmortem coccidioidal serological tests for the donor were negative, the donor no residing in the traditional areas of endemicity of *C. Immitis*, none other recipients of the donor presented coccidiomycosis manifestations over the time. Primary pulmonary coccidiomycosis is usually a self limited illnes, the presenting as acute respirtaory failure is distinctly uncommon, and has been most frecuently associated with underlying immunosupresive conditions, particulary steroid therapy and massive exposure to *C immitis*, very rarely primary pneumonia is overwhelming and complicated by respiratory failure and the mortality of acute disseminated coccidiomycosis is high, and the outcome may not be altered by antifungal therapy⁸.

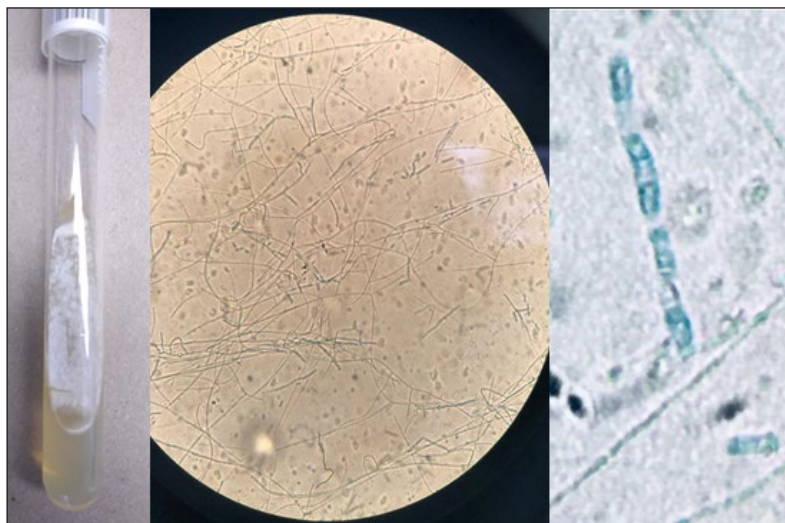


Figure 3. filamentous colonies, the cotton blue stain 40 x, reveled thin septate hyphae and arthroconidia.

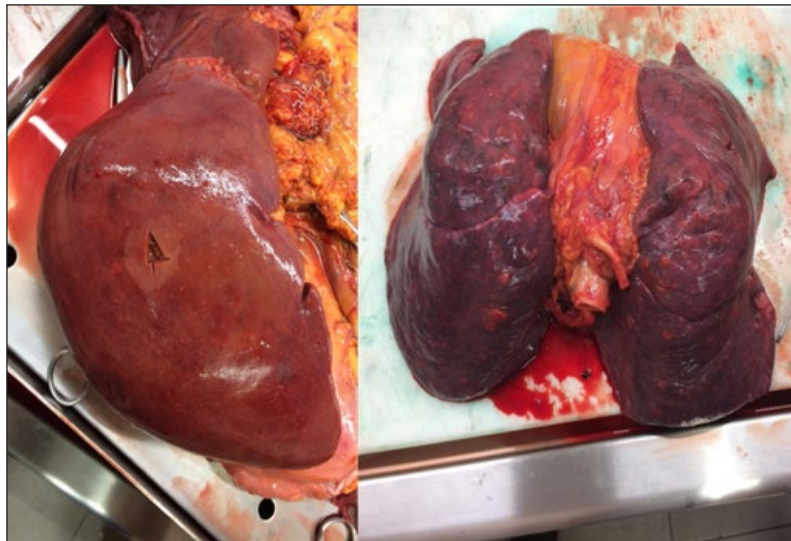

Figure 4. Post mortem macroscopic pieces shows a multiple nodular lesions in the lung and liver.

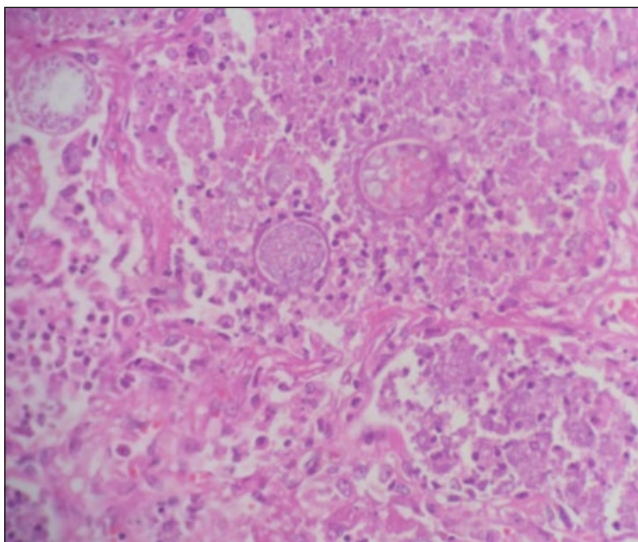


Figure 5. Granulomatous inflammation, large thick walled spherules contain variable sized daughter endospores.

The case that we are presenting add to the small list of reports documenting the occasionally acute and aggressive nature of the disseminated clinical form of coccidioidomycosis.

Ethical disclosure

Conflict of interest. None

Sources of funding for our research. Authors

Protection of human and animal subjects. Consent Written informed consent was obtained from the patient for publication of this case report and accompanying images.

Confidentiality of data. No data that identifies patient are revealed

References:

1. Matthay MA, Zemans RL, Zimmerman GA, et al. Acute respiratory distress syndrome. *Nat Rev Dis Primers*. 2019;5(1):18. Published 2019 Mar 14. doi:10.1038/s41572-019-0069-0
2. Ana Maria Lopez M.D, Paul L. Williams M.D., Visalia, California, Neil M. Ampel, M.D., Tucson, Arizona. Acute Pulmonary Coccidioidomycosis Mimicking Bacterial Pneumonia and Septic Shock: A Report of Two Cases August 1993 *The American Journal of Medicine* Volume 95.
3. Kelson Nobre Veras, Bruno C. De Souza Figueirêdo, Liliane Maria Soares Martins, Jayro T. Paiva Vasconcelos, Bodo Wanke. Coccidioidomycosis: an unusual cause of acute respiratory distress syndrome * Donor-derived Coccidioides immitis fungemia in solid organ transplant recipients (*J Pneumol* 2003;29(1):45-8)
4. E. Blodgett, P. Jan Geiseler, R.A. Larsen, M. Stapfer, Y. Qazi, L.M. Petrovic. Donor-derived Coccidioides immitis fungemia in solid organ transplant recipients. *Transpl Infect Dis* 2012; 14: 305–310.
5. Janis E. Blair, Division of Infectious Diseases, Mayo Clinic, Scottsdale, AZ Coccidioidomycosis in Liver Transplantation, *Liver Transpl* 12:31–39, 2006. © 2005 AASLD.
6. Jae Myung Cha, Multi-organ failure caused by reactivated coccidioidomycosis without dissemination in a patient with renal transplantation. *Respirology* (2000) 5, 87–90.
7. Stephanie L. Kokseng • Janis E. Blair Subclinical Dissemination of Coccidioidomycosis in a Liver Transplant Recipient, *Mycopathologia* (2011) 172:223–226.
8. Carlos A. Hartmann, Wint T. Aye & Janis E. Blair (2016) Treatment considerations in pulmonary coccidioidomycosis, *Expert Review of Respiratory Medicine*, 10:10, 1079-1091, DOI: 10.1080/17476348.2017.1234378
9. Janis E. Blair, Joy L. Logan, Coccidioidomycosis in Solid Organ Transplantation, *Clinical Infectious Diseases*, Volume 33, Issue 9, 1 November 2001, Pages 1536–1544, <https://doi.org/10.1086/323463>
10. Patty W. Wright, Demosthenes Pappagianis, Mark Wilson, Ana Louro, Stephen A. Moser, Kenneth Komatsu, Peter G. Pappas, Donor-Related Coccidioidomycosis in Organ Transplant Recipients, *Clinical Infectious Diseases*, Volume 37, Issue 9, 1 November 2003, Pages 1265–1269, <https://doi.org/10.1086/378741>