

Erythema nodosum leprosum: A pediatric case report successfully treated with thalidomide

Natalia Delgado^{1,2}, Jalil Rashid Forero^{1,3}, Pilar Pérez⁴, Rolando Rios⁵, Doris M. Salgado⁶, Andres Felipe Romero^{7,*}

Abstract

We present the case of a 10-year-old patient who visited our hospital with prolonged fever, multiple nodular lesions on the skin, and diagnostic studies that confirmed leprosy. As a complication, there is a type 2 leprosy reaction that does not respond adequately to the use of steroids; therefore, we used thalidomide, a medication that is infrequently used in children. However, we were able to control the inflammatory response.

Keywords: Leprosy, *Mycobacterium leprae*, Thalidomide.

Eritema Nodoso Leproso: Reporte de un caso pediátrico tratado exitosamente con talidomida.

Resumen

Presentamos el caso de un paciente de 10 años quien consulta a urgencias por presentar fiebre prolongada, múltiples lesiones nodulares en piel y reporte de paraclínicos que confirmaban lepra. Como complicación, presenta una reacción leprosa tipo 2 que no respondió de manera adecuada a esteroides sistémicos, por lo cual usamos talidomida, un medicamento poco usado en niños, pero con el cual logramos controlar la respuesta inflamatoria.

Palabras clave: Lepra, *Mycobacterium leprae*, Talidomida.

Introduction

Leprosy is a chronic, transmissible, and disabling infectious disease that affects the skin and peripheral nerves, caused by *Mycobacterium leprae* and *Mycobacterium lepromatosis*¹. This microorganism has a long incubation period, and for many years, it was thought to be an adult-exclusive disease; however, children who are exposed very early to high mycobacterial loads, especially from close contacts and cohabitants with leprosy, are at greater risk of developing the disease. *Mycobacterium leprae* and *Mycobacterium lepromatosis* are mainly transmitted through the respiratory secretions of infected individuals, as well as armadillo exposure².

Despite being considered a forgotten tropical disease, the World Health Organization (WHO) reported 133,781 cases in 2021, with 39% in women and 8,490 cases diagnosed with

grade 2 disability, including 4% in children. In Colombia, by 2021, 265 cases were reported in the country. Of these, 246 were confirmed by laboratory and 67 by clinical diagnosis. For the year 2023, the number of new cases in Colombia was 247, with no cases reported in individuals under 14 years of age. Apparently, this number seems to remain stable over time and it constitutes a significant problem in public health^{3,4,5}.

There are two types of leprosy reactions and acute inflammatory processes in patients: type 1 and type 2, the latter prevalent in lepromatous leprosy. These reactions are seldom described in children under 15 (between 1.36% and 29.7%, up to 50% in highly endemic areas). The underdiagnosis of this disease, along with various types of reactions, can result in preventable complications and disabilities if not promptly diagnosed and treated. This, in turn, can help shorten the transmission chain. The WHO classifies leprosy into two

1 Pediatric Resident, Department of Pediatrics, Universidad Surcolombiana, Neiva.

2 <https://orcid.org/0000-0002-5041-387X>

3 <https://orcid.org/0009-0008-7968-1123>

4 Pediatric Rheumatologist, Department of Pediatrics, Universidad Surcolombiana. Department of Pediatrics, Hospital Universitario de Neiva. <https://orcid.org/0000-0002-4756-6808>

5 Pediatric Nephrologist, Department of Pediatrics, Universidad Surcolombiana. Department of Pediatrics, Hospital Universitario de Neiva. <https://orcid.org/0009-0003-9928-1649>

6 Professor, Department of Pediatrics, Universidad Surcolombiana, Neiva. <https://orcid.org/0000-0002-1663-1996>

7 Pediatric infectious diseases specialist, Department of Pediatrics, Universidad Surcolombiana. Department of Pediatrics, Hospital Universitario de Neiva. <https://orcid.org/0000-0002-4124-5982>

* Autor para correspondencia:

Correo electrónico: andres.romero@usco.edu.co

Recibido: 10/02/2024; Aceptado: 18/06/2024

Cómo citar este artículo: N. Delgado, *et al.* Erythema nodosum leprosum: A pediatric case report successfully treated with thalidomide. *Infectio* 2024; 28(3): 199-202

<https://doi.org/10.22354/24223794.1192>

forms: paucibacillary leprosy, which involves fewer than 5 lesions without demonstrating the presence of bacilli in skin smears, and multibacillary leprosy, which includes 6 or more lesions, nerve involvement, or the presence of bacilli in skin smears regardless of the number of lesions. The WHO recommends multidrug therapy for all leprosy cases using dapsone, rifampicin, and clofazimine, adjusting its duration based on whether it is paucibacillary or multibacillary. Type 2 reactions, initially treated with systemic steroids, may require alternative strategies, with thalidomide being common despite its limited use in children under 15 years. A case is presented in which thalidomide effectively controlled a type 2 reaction in a 10-year-old patient with refractory multibacillary lepromatous leprosy who did not respond to steroid management.

Case Report

A ten-year-old boy, referred from primary care in May/2021, presented with a history of three years (onset in 2018) of swelling in hands and feet, nodular lesions on the face and limbs, and left cervical nodules (Figure 1). Despite prior topical treatments based on diagnoses such as cellulitis or dermatosis with hydrocortisone, betamethasone, clotrimazole, and moisturizers, a pending skin biopsy, multiple consultations did not yield improvement. A recent complete blood count (09/05/2021) revealed leukocytosis with neutrophilia, anemia, and normal platelets. Notably, altered renal function (creatinine 1.6 mg/dl, Glomerular Filtration Rate (GFR) 31.75 ml/min/1.73) prompted referral to our center.

Upon admission, physical examination revealed erythematous left tonsillar hypertrophy without exudate and a palpable induration (3 × 2 cm) in the left cervical region sugges-

tive of painless adenopathy without color changes. The skin exhibited a thickened epidermis with nodular lesions on the nose, cheeks, chin, thighs, and ankles. Additionally, hypopigmented, crusty, and erythematous lesions without secretions were observed on the face, thorax, abdomen, and extremities, along with nodular lesions in the distal part of the foreskin. The hands and feet showed indurated edema around the proximal and middle phalanges without joint limitation.

Upon admission to the emergency department, ampicillin/sulbactam 1.5 g IV every 8 hours (50 mg/kg dose adjusted by GFR) was initiated, in combination with clindamycin 300 mg IV every 6 hours (40 mg/kg/day) due to skin involvement. Comprehensive laboratory tests (Table 1, first hospitalization from 10-19/05/2021) revealed a negative autoimmune profile. Electrolytes showed slightly elevated phosphorus and potassium levels and compromised renal function with a GFR of 29 ml/min/1.73 m². Imaging studies, including renal ultrasound and Doppler imaging of the renal vessels revealed no abnormalities. Neck ultrasound on the indicated non-abscessed cervical adenitis, and the echocardiogram demonstrated normal parameters with good biventricular contractile function.

Upon evaluating the clinical findings of thickened skin, hypopigmented regions, and widespread nodular lesions on the nose, cheeks, chin, forehead, and ear pinnae resembling leonine facies, leprosy was suspected. A slit-skin sample confirmed leprosy histologically and was positive for Hansen's bacillus, with a bacillary index of 2.5. Multiple lesions were classified as multibacillary lepromatous leprosy according to WHO classification, prompting treatment with clofazimine, rifampicin, and dapsone. Following treatment initiation, rapid clinical improvement and favorable paraclinical results

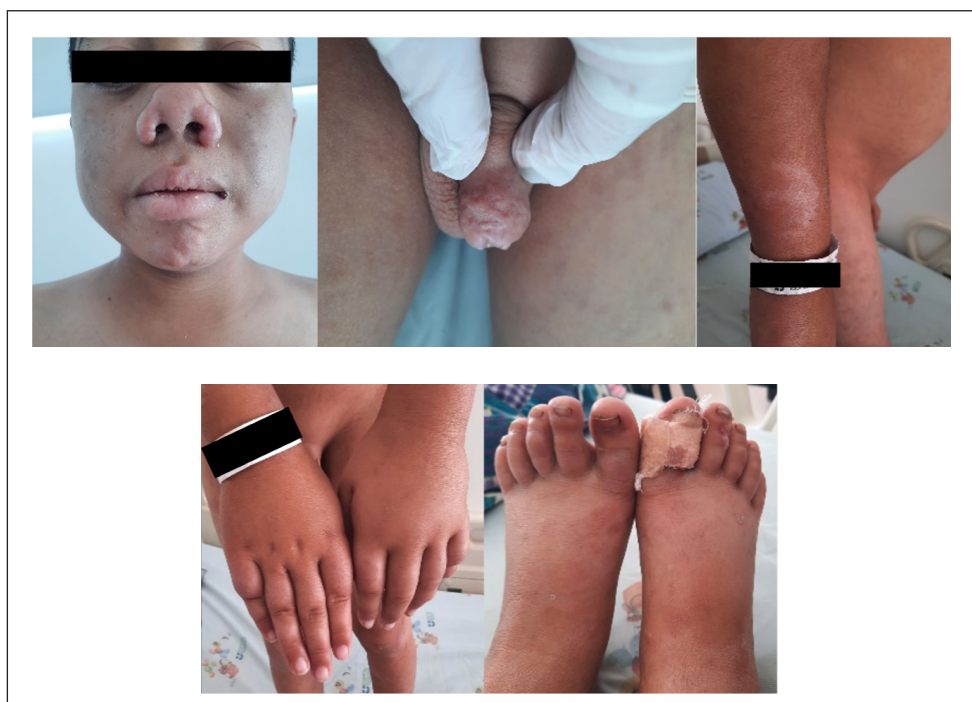

Figure 1. Leonine facies and nodules in extremities and penis

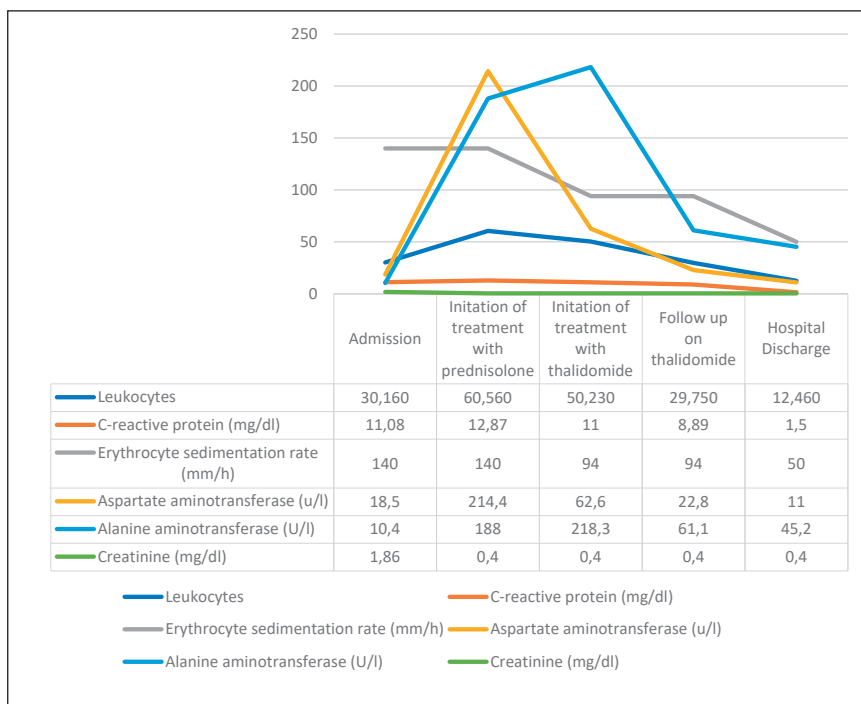


Table 1.

led to the decision to discharge the patient for outpatient management on 19/05/2021, five days after the beginning of the treatment.

The patient did not attend outpatient follow-ups, and two months after discharge (July/2021), he presented fever, lower limb edema and persistent skin lesions that were very painful, more nodular, and with changes in color; upon readmission to the emergency department (23/07/2021), general laboratory tests were performed, as shown in Table 1 (second hospitalization from 23/07/2021 – 20/08/2021).

Due to systemic involvement and increased lesions, a diagnosis of type 2 leprosy reaction, without uveitis, retinitis, or kidney injury, was made. The patient continued anti-leprosy therapy with clofazimine, rifampicin, and dapsone, along with high-dose steroids (Prednisone 1 mg/kg PO every 24 hours initiated on 26/07/2021). Antibiotics (Cefepime and Clindamycin) were initially administered but discontinued because of negative blood cultures. Despite two weeks of steroid treatment, active lesions persisted, necessitating venous Doppler revealing bilateral lymphedema, panniculitis, and nodular lesions. Follow-up tests indicated an unmodulated type 2 reaction. Thalidomide was initiated at a dose of 4 mg/kg/day (100 mg orally every night), resulting in resolution of fever, decreased edema, and improvement of paraclinical indicators within 72 hours. The patient met discharge criteria on 20/08/2021 for outpatient follow-up with thalidomide for two additional weeks and subsequent progressive dose reduction. Our patient comes from a family with a high degree of family dysfunction and resides with his mother, who works in agriculture and frequently changes residences. His mother is also illiterate. We were able to follow up with him for up

to six months after his hospital discharge; he continued to receive clofazimine, dapsone, and rifampicin, along with low doses of steroids and thalidomide^{6,7,8,9}. However, since then, we have not had any further contact with the patient or his mother. The mother was the index case, presenting multiple skin lesions suggestive of leprosy, but she refused diagnostic studies and, of course, treatment as well.

Discussion

Leprosy remains endemic, including in Colombia, where despite a decrease in reported cases in 2021, 5% of the 125 cases were in children under 15. The clinical presentation in children is akin to that in adults, ranging from tuberculoid to lepromatous forms, with a milder occurrence, especially in those with tuberculoid type leprosy and paucibacillary leprosy^{10,11}.

We report the case of a 10-year-old patient with a chronic clinical picture of nodular lesions that progressively extended until a large part of his body surface was compromised. His presentation differed from that reported globally in the literature, being diagnosed with lepromatous leprosy and multibacillary classification according to the WHO. In Cuba, Rumbaut-Castillo et al. reported a series of 50 cases in children, in which 78% of the patients presented with multibacillary leprosy at the time of diagnosis, similar to that presented in our patient. Likewise, the age of our patient coincides with the most frequent age of presentation described in the literature, which is 10–14 years, reflecting that there are still active areas of transmission¹². It is important to mention that the diagnosis and treatment of this patient were delayed, most likely due to the lack of awareness that this condition is still present in Colombia, and also that it can be seen in children.

Leprosy is known to cause long-term complications associated with physical disability secondary to vision loss and amputation; however, it can cause other immunologically mediated complications known as leprosy reactions. These reactions can occur before or during the treatment stage and are of two types: type 1, with a less severe presentation and usually associated with paucibacillary leprosy, and type 2, known as erythema nodosum leprosum, with a more severe and systemic presentation¹³. Our patient presented with a type 2 leprosy reaction, with subcutaneous and dermal nodules on the face, arms, thorax, abdomen, genital region, and lower extremities associated with persistent high fever, acute kidney injury, and panniculitis. Approximately 5–20% of children with leprosy present some leprosy reactions at some point before, during, or after treatment; however, in Brazil, a country with a high prevalence of leprosy, it was documented that in children under 15 years of age, the appearance of leprosy reactions was 52.9%, much higher than that reported in previous literature. The reactions occurred more frequently in children between 8 and 14 years of age who were diagnosed with multibacillary leprosy, with the type 1 reaction being much more frequent in 77.8% of the cases². The patient in this case was treated for lepromatous leprosy as recommended by the WHO with dapsona, rifampicin and clofazimine^{14,9} with adequate tolerance, but later presented with clinical and paraclinical manifestations of type 2 leprosy. To date, no studies have described the best therapy for the management of leprosy reactions in pediatrics; therefore, in our patient, we started treatment with corticosteroids, but after a week of treatment, the patient continued to deteriorate, so it was considered necessary to escalate therapy to thalidomide, a medication approved for the management of erythema nodosum leprosum in adults^{15,16}. After starting thalidomide, rapid improvement was observed, with resolution of fever, decrease in leukocytosis, and progressive resolution of skin lesions.

In summary, leprosy remains endemic to various Latin American countries, including Colombia. Early presumptive infection is crucial for mitigating long-term disability risk. While leprosy reactions are uncommon in pediatric cases, we present a successful case of thalidomide, a rare pediatric drug.

Ethical considerations

Financing. The study was not supported by any funding.

Ethical Compliance. This study was in accordance with the ethical standards of the institutional ethics committee and its approval. The informed consent was obtained.

Availability of data and materials. Not applicable.

Conflict of Interest. The authors declare that they have NO affiliations with or involvement in any organization or entity with any financial interest in the subject matter or materials discussed in this manuscript.

Author Contributions. ND and AFR conceived the original and supervised the writing, JRF, PP, RR and DMS help to the analysis of the results. All authors contributed to read and approved the version of the submitted manuscript.

References

- H. Serrano-Coll, H. R. Mora, J. C. Beltrán, M. S. Duthie, and N. Cardona-Castro, "Social and environmental conditions related to Mycobacterium leprae infection in children and adolescents from three leprosy endemic regions of Colombia," *BMC Infect. Dis.*, vol. 19, no. 1, pp. 1–10, 2019. <https://doi.org/10.1186/s12879-019-4120-2>
- S. S. Bandeira, C. A. Pires, and J. A. S. Quaresma, "Leprosy reactions in childhood: A prospective cohort study in the Brazilian amazon," *Infect. Drug Resist.*, vol. 12, pp. 3249–3257, 2019. <https://doi.org/10.2147/IDR.S217181>
- World Health Organization, "Leprosy (Hansen's disease)," *Leprosy (Hansen's disease)*, 2023. [Online]. Available: <https://www.who.int/data/gho/data/themes/topics/leprosy-hansens-disease>.
- C. L. P. Clavijo, "LEPRA INFORME DE EVENTO INSTITUTO NACIONAL DE SALUD," 2021. [Online]. Available: <https://www.ins.gov.co/buscador-eventos/Informesdeevento/LEPRA PE VI 2021.pdf>. [Accessed: 18-Oct-2021].
- N. Cardona-Castro, "Leprosy in Colombia," *Curr. Trop. Med. Reports*, vol. 5, no. 2, pp. 85–90, 2018. <https://doi.org/10.1007/s40475-018-0145-7>
- M. B. B. de Oliveira and L. M. Diniz, "Leprosy among children under 15 years of age: Literature review," *An. Bras. Dermatol.*, vol. 91, no. 2, pp. 196–203, 2016. <https://doi.org/10.1590/abd1806-4841.20163661>
- C. Beltrán-Alzate et al., "Leprosy Drug Resistance Surveillance in Colombia: The Experience of a Sentinel Country," *PLoS Negl. Trop. Dis.*, vol. 10, no. 10, pp. 1–12, 2016. <https://doi.org/10.1371/journal.pntd.0005041>
- P. Thangaraju, S. Venkatesan, M. Gurunthalingam, S. Babu, and T. Tamilselvan, "Rationale use of thalidomide in erythema nodosum leprosum—a non-systematic critical analysis of published case reports," *Rev. Soc. Bras. Med. Trop.*, vol. 53, pp. 1–9, 2020. <https://doi.org/10.1590/0037-8682-0454-2019>
- WHO, "Guidelines for the Diagnosis, Treatment and Prevention of Leprosy," *Oms*, pp. 1–87, 2018.
- I. M. Romero-Montoya, J. C. Beltrán-Alzate, D. C. Ortiz-Marín, A. Díaz-Díaz, and N. Cardona-Castro, "Leprosy in colombian children and adolescents," *Pediatr. Infect. Dis. J.*, vol. 33, no. 3, pp. 321–322, 2013. <https://doi.org/10.1097/INF.0000000000000057>
- V. S. Santos, L. C. Santos, L. V. R. Lôbo, L. M. D. Lemos, R. Q. Gurgel, and L. E. Cuevas, "Leprosy and disability in children younger than 15 years in an endemic area of Northeast Brazil," *Pediatr. Infect. Dis. J.*, vol. 34, no. 3, pp. e44–e47, 2015. <https://doi.org/10.1097/INF.0000000000000592>
- R. R. Castillo et al., "Leprosy in children in cuba: Epidemiological and clinical description of 50 cases from 2012–2019," *PLoS Negl. Trop. Dis.*, vol. 15, no. 10, pp. 1–13, 2021. <https://doi.org/10.1371/journal.pntd.0009910>
- A. Pulido-Pérez, M. D. Mendoza-Cembranos, J. A. Avilés-Izquierdo, and R. Suárez-Fernández, "Eritema nodoso leproso y reacción de reversión en 2 casos de lepra importada," *Actas Dermosifiliogr.*, vol. 104, no. 10, pp. 915–919, 2013. <http://dx.doi.org/10.1016/j.ad.2012.09.009>
- D. P. Legendre, C. A. Muzny, and E. Swiatlo, "Hansen's disease (Leprosy): Current and future pharmacotherapy and treatment of disease-related immunologic reactions," *Pharmacotherapy*, vol. 32, no. 1, pp. 27–37, 2012.
- B. Upputuri, M. S. Pallapati, P. Tarwater, and A. Srikantam, "Thalidomide in the treatment of erythema nodosum leprosum (ENL) in an outpatient setting: A five-year retrospective analysis from a leprosy referral centre in India," *PLoS Negl. Trop. Dis.*, vol. 14, no. 10, pp. 1–13, 2020. <https://doi.org/10.1002/PHAR.1009>
- P. do S. S. Costa, L. R. Fraga, T. W. Kowalski, E. L. R. Daxbacher, L. Schuler-Faccini, and F. S. L. Vianna, "Erythema Nodosum Leprosum: Update and challenges on the treatment of a neglected condition," *Acta Trop.*, vol. 183, pp. 134–141, 2018. <https://doi.org/10.1016/j.actatropica.2018.02.026>